

# Cigarette smoke exposure potentiates bleomycin-induced lung fibrosis in guinea pigs

José Cisneros-Lira, Miguel Gaxiola, Carlos Ramos, Moisés Selman and Annie Pardo

*Am J Physiol Lung Cell Mol Physiol* 285:L949-L956, 2003. First published 3 July 2003; doi:10.1152/ajplung.00074.2003

## You might find this additional info useful...

---

This article cites 50 articles, 26 of which can be accessed free at:

<http://ajplung.physiology.org/content/285/4/L949.full.html#ref-list-1>

This article has been cited by 5 other HighWire hosted articles

### **Workshop on Idiopathic Pulmonary Fibrosis in Older Adults**

Richard J. Castriotta, Basil A. Eldadah, W. Michael Foster, Jeffrey B. Halter, William R. Hazzard, James P. Kiley, Talmadge E. King, Jr, Frances McFarland Horne, Susan G. Nayfield, Herbert Y. Reynolds, Kenneth E. Schmader, Galen B. Toews and Kevin P. High  
*Chest*, September, 2010; 138 (3): 693-703.

[\[Abstract\]](#) [\[Full Text\]](#) [\[PDF\]](#)

### **Cigarette Smoking Is Associated with Subclinical Parenchymal Lung Disease: The Multi-Ethnic Study of Atherosclerosis (MESA)-Lung Study**

David J. Lederer, Paul L. Enright, Steven M. Kawut, Eric A. Hoffman, Gary Hunninghake, Edwin J. R. van Beek, John H. M. Austin, Rui Jiang, Gina S. Lovasi and R. Graham Barr  
*AJRCCM*, August 21, 2009; 180 (5): 407-414.

[\[Abstract\]](#) [\[Full Text\]](#) [\[PDF\]](#)

### **Idiopathic Pulmonary Fibrosis: Outcome in Relation to Smoking Status**

Katerina M. Antoniou, David M. Hansell, Michael B. Rubens, Katharina Marten, Sujal R. Desai, Nikolaos M. Siafakas, Andrew G. Nicholson, Roland M. du Bois and Athol U. Wells  
*AJRCCM*, December 28, 2007; 177 (2): 190-194.

[\[Abstract\]](#) [\[Full Text\]](#) [\[PDF\]](#)

### **Matrix Metalloproteases in Aberrant Fibrotic Tissue Remodeling**

Annie Pardo and Moisés Selman  
*procats*, May 31, 2006; 3 (4): 383-388.

[\[Abstract\]](#) [\[Full Text\]](#) [\[PDF\]](#)

### **Smoking: An Injury with Many Lung Manifestations**

Kevin R. Flaherty M.D. and Gary G. Hunninghake  
*AJRCCM*, October 25, 2005; 172 (9): 1070-1071.

[\[Full Text\]](#) [\[PDF\]](#)

Updated information and services including high resolution figures, can be found at:

<http://ajplung.physiology.org/content/285/4/L949.full.html>

Additional material and information about *AJP - Lung Cellular and Molecular Physiology* can be found at:

<http://www.the-aps.org/publications/ajplung>

---

This information is current as of March 23, 2011.

# Cigarette smoke exposure potentiates bleomycin-induced lung fibrosis in guinea pigs

José Cisneros-Lira,<sup>1,2</sup> Miguel Gaxiola,<sup>2</sup> Carlos Ramos,<sup>2</sup> Moisés Selman,<sup>2</sup> and Annie Pardo<sup>1</sup>

<sup>1</sup>Facultad de Ciencias, Universidad Nacional Autónoma de México, Circuito Exterior S/N, Mexico City 04000; and <sup>2</sup>Instituto Nacional de Enfermedades Respiratorias, Tlalpan 4502, Mexico City, Mexico

Submitted 13 March 2003; accepted in final form 30 June 2003

**Cisneros-Lira, José, Miguel Gaxiola, Carlos Ramos, Moisés Selman, and Annie Pardo.** Cigarette smoke exposure potentiates bleomycin-induced lung fibrosis in guinea pigs. *Am J Physiol Lung Cell Mol Physiol* 285: L949–L956, 2003. First published July 3, 2003; 10.1152/ajplung.00074.2003.—The role of tobacco smoking in the development and outcome of pulmonary fibrosis is uncertain. To approach the effects of cigarette smoke on bleomycin-induced lung fibrosis, we studied five groups of guinea pigs: 1) controls, 2) instilled with bleomycin (B), 3) exposed to tobacco smoke for 6 wk (TS), 4) bleomycin instillation plus tobacco smoke exposure for 6 wk (B+TS), and 5) tobacco smoke exposure for 6 wk and bleomycin after smoking (TS/B). Guinea pigs receiving bleomycin and tobacco smoke exposure exhibited higher fibrotic lesions including a significant increase in the number of positive  $\alpha$ -smooth muscle actin cells compared with bleomycin alone (B+TS,  $3.4 \pm 1.2\%$ ; TS/B,  $3.7 \pm 1.5\%$ ; B,  $2.3 \pm 1.5\%$ ;  $P < 0.01$ ). However, only the TS/B group reached a significant increase in lung collagen compared with the bleomycin group (TS/B,  $3.5 \pm 0.7$ ; B + TS,  $2.9 \pm 0.4$ ; B,  $2.4 \pm 0.2$  mg hydroxyproline/lung;  $P < 0.01$ ). Bronchoalveolar lavage (BAL) from TS/B showed an increased number of eosinophils and higher levels of IL-4 and tissue inhibitor of metalloproteinase-2 ( $P < 0.01$  for all comparisons) and induced a significant increase in fibroblast proliferation ( $P < 0.05$ ). Importantly, smoke exposure alone induced an increase in BAL neutrophils, matrix metalloproteinase-9, and fibroblast proliferation compared with controls, suggesting that tobacco smoke creates a profibrotic milieu that may contribute to the increased bleomycin-induced fibrosis.

matrix metalloproteinase-9; fibroblast proliferation; interleukin-4; tissue inhibitor of metalloproteinase-2; pulmonary fibrosis

PULMONARY FIBROSIS is the final common pathway of a variety of disorders affecting the lung parenchyma and grouped as interstitial lung diseases (ILD) (39). Cigarette smoking, a leading cause of chronic obstructive pulmonary disease (COPD), also exerts an effect on parenchymal lung inflammation and fibrosis. Thus it may promote or inhibit these pathological processes, and, in turn, it may influence the incidence, severity, or natural history of a wide array of ILD (25). For example, it is strongly associated with some diseases that seem to be likely caused by smoking, such as respiratory bronchiolitis-associated ILD, desquamative inter-

stitial pneumonia, and pulmonary histiocytosis X (25, 26, 47, 49). Likewise, current and former smokers show an increased risk for developing idiopathic pulmonary fibrosis (IPF), although smokers appear to have a better survival rate than nonsmokers (3, 21). By contrast, cigarette smoking seems to have a protective effect on the development of hypersensitivity pneumonitis, a lymphocytic alveolitis provoked by the exposure to organic particles, and sarcoidosis, an inflammatory disorder of unknown etiology (10, 11, 25, 41). In addition, a number of clinical and experimental studies suggest that cigarette smoking reduces the frequency of radiation-induced pneumonitis (18, 28).

The mechanisms by which cigarette smoking affects in one or another way the inflammatory and fibrotic responses of the lung remain to be elucidated. Cigarette smoke seems on one hand to suppress some macrophage activities but, on the other, to promote systemic priming of neutrophils (2, 6).

Tobacco smoke may participate in lung remodeling by increasing the expression of a number of cytokines and by inducing the release of profibrotic growth factors bound to extracellular matrix through the increase of the expression of matrix metalloproteinases (MMP) (24).

It has been shown that epithelial cells from small airways of smokers and COPD patients highly express transforming growth factor (TGF)- $\beta$ 1 mRNA and protein (46). This finding may contribute to the fibrotic reaction in targets areas of the lungs. Thus, in a study comparing smokers and nonsmoking males of various ages who died suddenly, it was found that bronchiolar inflammatory changes were evident in smokers of all ages, and bronchiolar fibrosis was clearly associated with chronic cigarette use, both lesions occurring independently of emphysema (1).

An important consideration in the putative interactions between cigarette smoking and incidence or course of an ILD is related with the timing relationship between tobacco smoke exposure and the fibrogenic injury. In this context, the aim of this study was to examine the effect of previous and simultaneous side-stream cigarette smoking on bleomycin-induced lung fibrosis in guinea pigs.

Address for reprint requests and other correspondence: A. Pardo, Facultad de Ciencias, UNAM, Apartado Postal 21-630, Coyoacan México DF, 04000, Mexico (E-mail: aps@hp.fciencias.unam.mx).

The costs of publication of this article were defrayed in part by the payment of page charges. The article must therefore be hereby marked "advertisement" in accordance with 18 U.S.C. Section 1734 solely to indicate this fact.

## MATERIALS AND METHODS

**Tobacco smoke and bleomycin exposure.** Guinea pigs (~400 g) were exposed to the smoke of 20 filtered commercial cigarettes (Marlboro 100, Cigatam SA de CV, Mexico; Philip Morris Products) per day, 5 days/wk for 6 wk as previously described (43). Bleomycin (3 units; Bristol-Myers, Syracuse, NY) was administered by single intratracheal instillation.

**Experimental design.** Five groups of guinea pigs were studied: 1) treated with bleomycin and killed 6 wk after (B); 2) exposed to tobacco smoke for 6 wk and killed after treatment (TS); 3) instilled with bleomycin and then exposed to tobacco smoke during 6 wk (B+TS); 4) exposed first to tobacco smoke for 6 wk and then instilled with bleomycin and killed 6 wk after (TS/B); and 5) control age-matched guinea pigs exposed to room air and instilled with saline solution (C). The Committee on Use and Care of Animals from the National Institute of Respiratory Diseases approved the protocol.

Eight animals from each group were anesthetized with 50 mg/kg ip pentobarbital sodium, and lungs were obtained for histology and hydroxyproline quantification.

**Histology.** Lungs were lavaged with saline solution through the main pulmonary artery, and the right lung was removed and inflated with 4% paraformaldehyde at continuous pressure of 25 cmH<sub>2</sub>O. Tissues were embedded in paraffin and processed for conventional light microscopy and immunohistochemistry. The whole left lung was removed and homogenized in 10 ml of PBS, and aliquots (1 ml) of lung homogenates were kept at -80°C until used.

**Hydroxyproline measurement.** Left lungs from eight guinea pigs of each group were analyzed for hydroxyproline content as an estimate of collagen content. Aliquots of 1 ml of homogenate were hydrolyzed in 1 ml of 12 N HCl for 24 h at 110°C, and hydroxyproline colorimetric analysis was performed as described by Woessner (48). All assays were done in triplicate, and data are expressed as micrograms of hydroxyproline per lung.

**Bronchoalveolar lavage.** In a parallel experiment, left lungs from six animals of each group were lavaged through a tracheal cannula with three aliquots of 5 ml of sterile saline solution at 37°C. The bronchoalveolar lavage (BAL) fluid was centrifuged at 400 g for 10 min at 4°C, and the supernatant was kept at -80°C until use. The pellet was resuspended in PBS and used for total cell count. Differential cell counting was performed after fixation with 50% ethyl alcohol and 2% Carbowax (50% polyethylene glycol) in slides stained with hematoxylin and eosin. Recovered fluid was used to evaluate fibroblast proliferation, IL-4, tissue inhibitor of metalloproteinase (TIMP)-2, and cell profile. Right lungs were used for zymography.

**Lung tissue zymography.** Lung samples (25 mg/ml) were homogenized in 10 mM 3-[(3-cholamidopropyl)dimethylammonio]-1-propanesulfonate, 20 mM HEPES (pH 7.5), and 150 mM NaCl and then centrifuged at 9,500 g for 20 min at 4°C. Lung supernatants containing 15 µg of protein were analyzed by SDS-PAGE gels (8.5%) containing gelatin (1 mg/ml) and a final concentration of 0.3 mg/ml heparin (51). Serum-free conditioned medium from human lung fibroblasts was used as an MMP-2 marker, and conditioned medium from PMA-stimulated human osteogenic sarcoma bone [U2-OS cells from American Type Culture Collection (ATCC), Rockville, MD] was utilized as an MMP-9 marker.

**Quantification of IL-4 and TIMP-2 in BAL fluid.** BAL fluid samples from six animals of the several groups were 4× concentrated, and IL-4 concentration was determined by enzyme-linked immunosorbent assay (ELISA) with the kit Quantikine HS (R&D Systems, Minneapolis, MN) according

to the manufacturer's instructions. Levels of TIMP-2 were determined in the same samples by a human ELISA system (Amersham Pharmacia Biotech, Piscataway, NJ) that can detect TIMP-2 from guinea pigs. The assays were performed in quadruplicate.

**Lung fibroblast growth rate.** Guinea pig lung fibroblast cell line JH4 was purchased from ATCC. Fibroblasts (passages 5-8) were cultured in T-25 cm<sup>2</sup> Falcon flasks with Ham's F-12 medium (GIBCO-BRL, Grand Island, NY) supplemented with 10% fetal bovine serum (FBS, GIBCO-BRL), 100 U/ml penicillin, and 100 mg/ml streptomycin at 37°C in 5% CO<sub>2</sub>-95% air. Fibroblasts were plated in 96-well culture plates at a cell density of 7 × 10<sup>3</sup> cells/well under the same culture conditions and, after 12 h, replaced with new medium plus 1% FBS alone or with 1% FBS and 20% of 4× concentrated and sterilized (PVDF 0.22-µm Millex-GV; Millipore, Molsheim, France) BAL fluid from control or experimental guinea pigs. After 96 h, cell growth was determined with the cell proliferation reagent WST-1 (Boehringer Mannheim) as previously described (37). Absorbance was measured with an ELISA plate reader at a wavelength of 450 nm using a reference wavelength of 620 nm. Absorbance changes were taken as percentage of growth rate increase related to basal values (*day 0*). All assays were performed in sextuplicate. To analyze inhibition of cell proliferation, we ran a parallel experiment using anti-IL-4 neutralizing antibody (R&D Systems).

**Immunohistochemistry.** Sections were incubated with monoclonal mouse anti-human α-smooth muscle actin (SMA; DAKO, Carpinteria, CA), anti-human TIMP-2 (Oncogene, San Diego, CA), and anti-human IL-4 (Santa Cruz Biotechnology, Santa Cruz, CA) at 4°C overnight. A secondary biotinylated anti-immunoglobulin followed by horseradish peroxidase-conjugated streptavidin (BioGenex, San Ramon, CA) was used according to the manufacturer. 3-Amino-9-ethylcarbazole (BioGenex) was used as substrate (44). The primary antibody was replaced by nonimmune serum for negative control slides. In addition, we determined the number of α-SMA-positive cells in lung sections of B, B+TS, and TS/B animals by evaluating 20 fields of fibrotic and inflammatory sections.

**Evaluation of α-SMA.** The ratio of α-SMA-positive cells in lung sections of B, B+TS, and TS/B animals was determined in 20 fields of fibrotic and inflammatory sections from six animals in each group. Photographs were taken with a ×40 objective on a Nikon Eclipse E600 interfaced to a Sony SSC-DC54A digital camera system. Each image was processed into the image analysis program MetaMorph 4.5 (Universal Imaging). A threshold was set automatically, and total cell number in each image was determined by nuclei counts, then a new threshold was set on the positive-staining cells, and smooth muscle cells of the bronchioles, blood vessels, and alveolar rings were manually removed from the data set. Approximately the same number of cells was counted for all slides (3,304-4,074).

**Statistical analysis.** All values are expressed as means ± SD. Differences between means values were assayed by a one-way analysis of variance, using Tukey's method.

## RESULTS

**Lung histopathology and α-SMA-positive cells.** Lung tissue sections were prepared for immunohistochemistry using α-SMA antibody and counterstained with hematoxylin to appreciate tissue architecture. As shown in Fig. 1, control animals exhibited normal parenchymal histology, and α-SMA-positive cells were

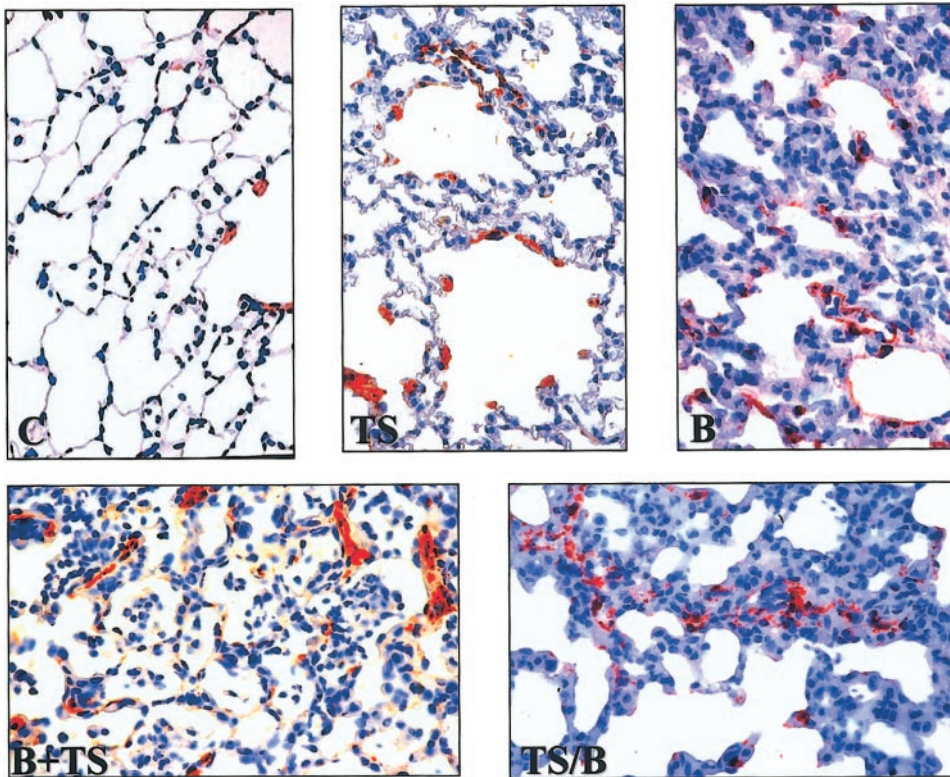


Fig. 1. Photomicrographs of guinea pig lung tissue sections in which immuno-reactive  $\alpha$ -smooth muscle actin (SMA) was revealed by 3-amino-9-ethyl-carbazole and counterstained with hematoxylin. C, control lungs; TS, exposure to tobacco smoke for 6 wk; B, bleomycin-treated guinea pigs killed after 6 wk. B+TS, bleomycin instillation plus tobacco smoke exposure during 6 wk. TS/B, tobacco smoke exposure for 6 wk and then bleomycin instillation. Original magnification,  $\times 40$ . The photomicrographs are representative of 6 animals from each experimental group and were selected to illustrate the extent and pattern of lung alveolar inflammation and fibrosis and the  $\alpha$ -SMA staining.

apparent in alveolar rings. Lungs from guinea pigs exposed to tobacco smoke showed a moderate peribronchiolar, alveolar, and interstitial inflammation consisting mostly of mononuclear cells and some areas with mild to moderate emphysematous lesions. As in controls, in these animals  $\alpha$ -SMA-positive cells were mainly located in smooth muscle cells from vessels and in alveolar rings. At 6 wk after bleomycin instillation, the lungs displayed focal areas of inflammation and interstitial fibrosis, with the presence of  $\alpha$ -SMA-positive cells in areas of thickened alveolar septa. Guinea pigs in the B+TS group showed a more evident loss of lung architecture with large zones of inflammation and interstitial fibrosis where an increased number of  $\alpha$ -SMA-positive cells was apparent. In guinea pigs that were exposed to cigarette smoking first and then to bleomycin (TS/B), there was a more severe inflammatory and fibrotic lesion and numerous  $\alpha$ -SMA-positive cells in the areas of fibrosis.

We determined the ratio of  $\alpha$ -SMA-positive cells per 100 cells in lung sections of B, B+TS, and TS/B animals by digital imaging, counting 20 fields of fibrotic and inflammatory sections from six animals in each group. Lungs from both groups that were exposed to tobacco smoke and bleomycin exhibited a significant increase in the number of these cells compared with animals treated only with bleomycin (TS/B,  $3.7 \pm 1.5\%$ ; B+TS,  $3.4 \pm 1.2\%$  vs. B,  $2.3 \pm 1.5\%$ ;  $P < 0.01$ ).

**Lung hydroxyproline content.** Lung collagen was quantified by measuring hydroxyproline content (Fig. 2). Lungs from TS guinea pigs did not show differences with controls ( $1.4 \pm 0.2$  vs.  $1.2 \pm 0.2$  mg hydroxypro-

line/lung). At 6 wk after bleomycin instillation, a significant increase in lung hydroxyproline was noticed in all three groups receiving bleomycin when compared with controls (B,  $2.4 \pm 0.2$ ; B+TS,  $2.9 \pm 0.4$ ; TS/B,  $3.5 \pm 0.7$  mg/lung vs.  $1.2 \pm 0.2$  mg/lung from C;  $P < 0.01$ ). When these three groups were compared, a significant increase in lung hydroxyproline was found in those guinea pigs that received tobacco smoke first and bleomycin after, compared with the group that received bleomycin alone ( $3.5 \pm 0.7$  vs.  $2.4 \pm 0.2$  mg/lung;  $P < 0.01$ ).

**BAL cell profile.** Results of cell profile analysis from BAL are shown in Fig. 3. A significant increase in the

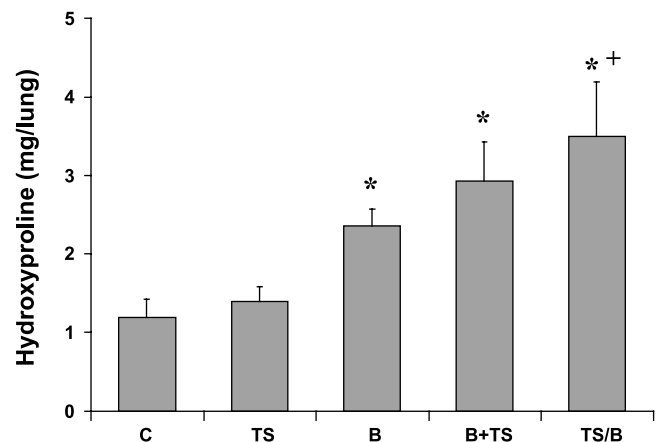


Fig. 2. Effect of tobacco smoke and/or bleomycin instillation on lung hydroxyproline. \* $P < 0.01$  compared with control; + $P < 0.01$  compared with the other 2 groups that received bleomycin.

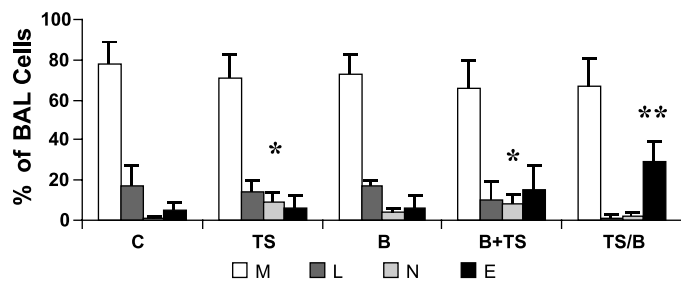


Fig. 3. Cellular profile in the bronchoalveolar lavage (BAL) of control animals (C) and animals exposed to tobacco smoke (TS), bleomycin (B), bleomycin plus tobacco smoke (B+TS), and tobacco smoke first and bleomycin treatment after (TS/B). M, macrophages; L, lymphocytes; N, neutrophils; E, eosinophils. \* $P < 0.05$  for neutrophils compared with all other groups; \*\* $P < 0.05$  for eosinophils compared with all the groups.

percentage of neutrophils was observed in TS and B+TS compared with C ( $9.5 \pm 4.9$ ,  $8 \pm 4.8$ , and  $0.8 \pm 0.8\%$ , respectively;  $P < 0.05$ ). The group receiving first tobacco smoke and then bleomycin revealed a significant increase in the percentage of eosinophils (TS/B,  $29.7 \pm 10\%$ ; B+TS,  $15.4 \pm 12\%$ ; B,  $6.1 \pm 6.0\%$ ; TS,  $6.2 \pm 5.9\%$ ; and C,  $4.8 \pm 4.4\%$ ;  $P < 0.05$ ).

**Fibroblasts growth rate.** To determine whether BAL fluid derived from the different experimental groups had an effect on lung guinea pig fibroblast growth rate, we determined cell number 96 h after BAL fluid exposure, using the cell proliferation reagent WST-1.

As shown in Fig. 4, fibroblasts incubated with BAL from control animals exhibited a  $6.3 \pm 1.2\%$  increase in growth rate over fibroblasts in presence of 1% FBS. When cells were incubated with BAL derived from the different experimental groups (TS, B, B+TS, and TS/B), all of them displayed significant increases in growth rate compared with control (TS,  $53.8 \pm 1.8\%$ ; B,  $50.6 \pm 4.5\%$ ; B+TS,  $66.6 \pm 2.6\%$ ; TS/B,  $83.4 \pm 4.6\%$ ;  $P < 0.05$ ). In addition, BAL from TS/B displayed a significant increase compared with tobacco smoke or bleomycin alone ( $P < 0.01$ ). Anti-IL-4 antibody significantly inhibited cell proliferation in the TS/B group ( $62.7 \pm 3.4\%$ ,  $P < 0.01$ ).

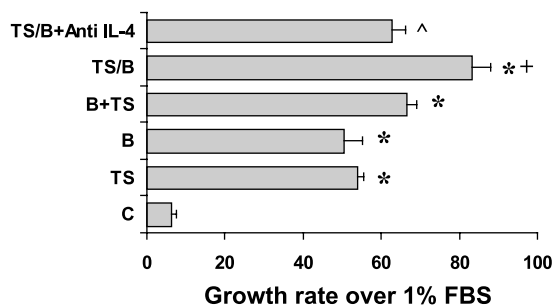


Fig. 4. Growth rate analysis estimated by WST-1 assay from guinea pig lung fibroblasts after 4 days incubation in Ham's nutrient medium supplemented with 1% FCS and 20% of 4 $\times$  concentrated BAL from C, TS, B, B+TS, TS/B, and TS/B with anti-IL-4 neutralizing antibody (TS/B+Anti IL-4). Results are expressed as means  $\pm$  SD. \* $P < 0.05$  compared with control; +  $P < 0.01$  compared with TS and B; ^  $P < 0.01$  compared with TS/B.

**IL-4 and TIMP-2 in BAL fluid.** ELISA was performed to determine whether protein levels of chemokines/cytokines were present in BAL fluids that might be associated with fibroblast proliferation. From the several molecules analyzed, only IL-4 and TIMP-2 revealed some differences among the groups tested. As shown in Fig. 5A, there was a significant increase in IL-4 levels in TS/B when all the groups are compared [ $18.1 \pm 5.5$  (TS/B) vs.  $12.4 \pm 1.9$  (C);  $11.2 \pm 2.8$  (TS);  $8.3 \pm 2.7$  (B) and  $11.3 \pm 2.7$  (B+TS) pg/mg protein;  $P < 0.05$ ].

Figure 5B shows the results of TIMP-2. A significant increase in BAL fluid TIMP-2 levels was observed in the TS/B group ( $213.8 \pm 53.5$  ng/mg protein) compared with the other groups, in which TIMP-2 exhibited very similar values ( $72.3 \pm 5.1$  in C,  $68.3 \pm 13.4$  in TS,  $80.7 \pm 9.2$  in B, and  $107.1 \pm 14.6$  in B+TS;  $P < 0.01$ ).

**Immunolocalization of IL-4 and TIMP-2.** To examine the cell source of IL-4 and TIMP-2, we evaluated the expression of the immunoreactive proteins in control guinea pigs and in those exposed to bleomycin alone and to tobacco smoke and bleomycin. As illustrated in Fig. 6, IL-4 and TIMP-2 are mainly expressed by interstitial and alveolar macrophages in bleomycin-instilled animals (Fig. 6, C and D) as well as in TS/B lungs (Fig. 6, E and F). Normal lungs were usually negative, as exemplified in Fig. 6, A and B, for IL-4 and TIMP-2, respectively. Samples incubated with nonimmune serum were negative as shown in Fig. 6G.

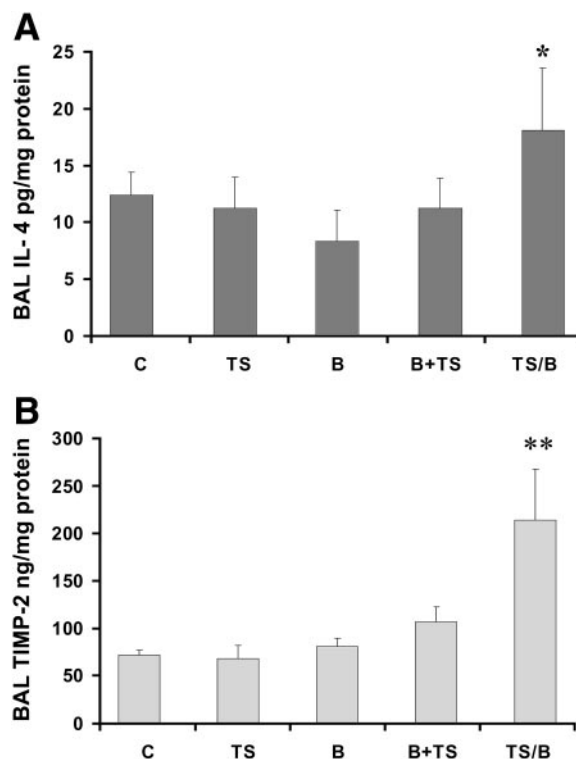


Fig. 5. Levels of IL-4 (A) and tissue inhibitor of metalloproteinase (TIMP)-2 (B) in BAL fluid. IL-4 and TIMP-2 were determined by ELISA in C, TS, B, B+TS, and TS/B animals. \* $P < 0.05$ ; \*\* $P < 0.01$ . The data represent the means  $\pm$  SD of 5 different animals.

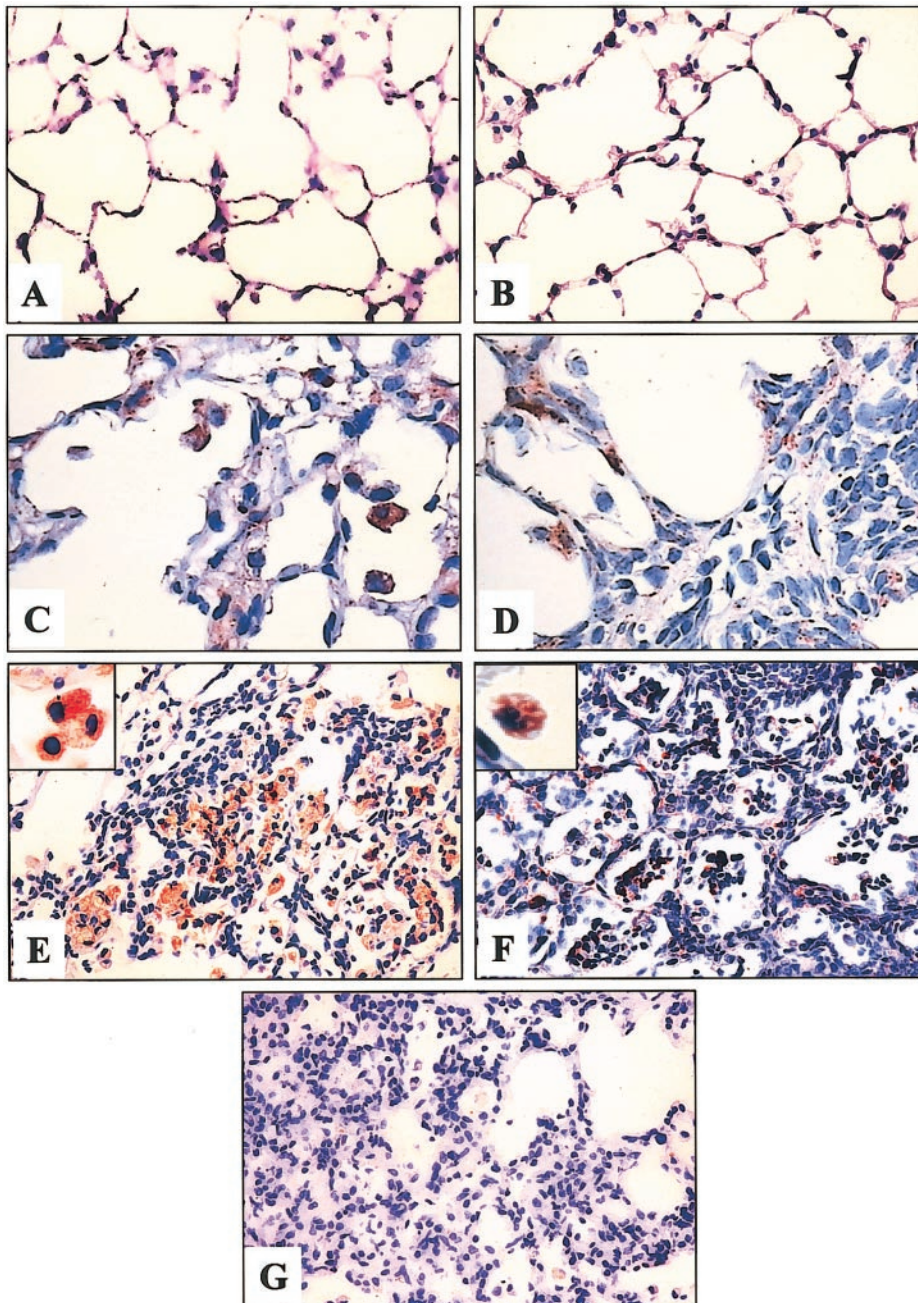


Fig. 6. Localization of IL-4 and TIMP-2 in guinea pig lung samples of bleomycin alone (C and D)- and tobacco smoke-exposed guinea pigs then treated with bleomycin (E and F). Immunoreactive proteins were revealed with 3-amino-9-ethyl-carbazole, and samples were counterstained with hematoxylin. A: control lung for IL-4. B: control lung for TIMP-2. C: IL-4-labeled macrophages. D: TIMP-2 labeled in macrophages (original magnification,  $\times 60$ ). E: numerous IL-4-labeled macrophages (original magnification,  $\times 40$ ); inset at high-power magnification ( $\times 100$ ). F: immunoreactive TIMP-2-positive-stained alveolar macrophages ( $\times 40$ ); inset,  $\times 100$ . G: negative control section from a guinea pig lung sample of TS/B in which the primary antibody was omitted ( $\times 40$ ).

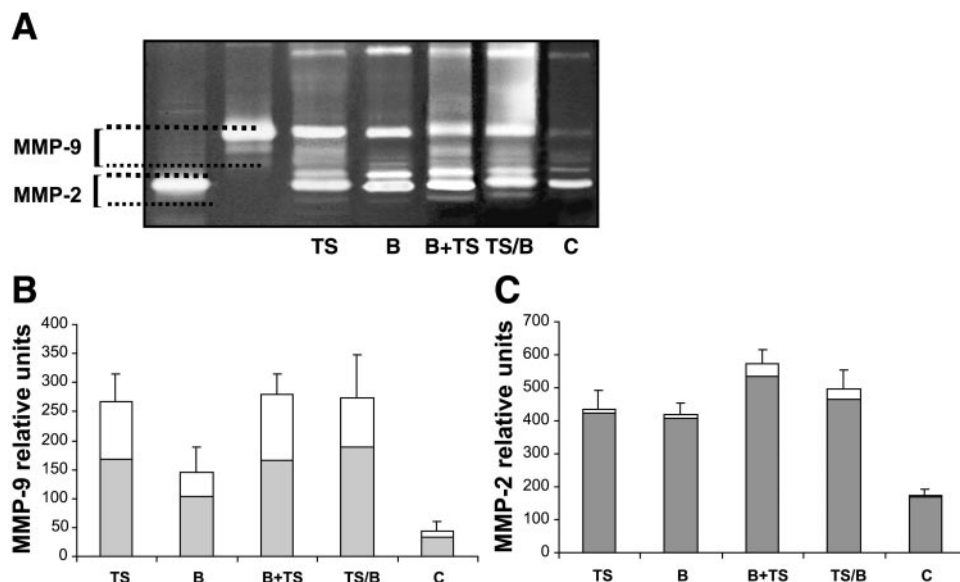
**Lung tissue zymography.** To analyze gelatinases activity, we examined lung tissues obtained from controls and experimental groups by gelatin zymography. A representative sample per group and a densitometric quantification of the surface and intensity of the lysis bands of zymograms derived from four different animals in each group are illustrated in Fig. 7. Total MMP-9, representing pro-MMP-9 and its lower-molecular-weight active form, was increased about threefold in lung samples from bleomycin group compared with control and about sixfold in the three experimental groups that were exposed to tobacco smoke. An active MMP-9 band represented  $\sim 23$ – $41\%$  of total MMP-9 and was more highly present in the groups receiving

tobacco smoke at the time of death (TS and TS+B). Likewise, total MMP-2 was increased two- to threefold in lung samples from all experimental groups compared with control. The active lower-molecular-weight form represented 2–7% of total MMP-2 lysis bands.

## DISCUSSION

The mechanisms by which exposure to cigarette smoking affects in one way or another the incidence or severity of various interstitial lung diseases are not entirely clear (25). Likewise, although smoking causes a number of cellular alterations in the airways, its role in parenchymal lung fibrogenesis has not been pre-

Fig. 7. Identification of gelatinolytic activities in lung tissues. Supernatants from a representative sample from lung tissue extracts from experimental and control animals were resolved by SDS-PAGE gels (8.5%) containing gelatin (1 mg/ml) and a final concentration of 0.3 mg/ml heparin. A: serum-free conditioned medium from human lung fibroblasts was used as matrix metalloproteinase (MMP)-2 marker (lane 1), and conditioned medium from PMA-stimulated U2-OS cells was utilized as MMP-9 marker (lane 2). B and C: densitometric analysis of 4 animals in each group is shown for MMP-9 and MMP-2 in the graphics. White fractions in the bars represent active MMPs, and the gray fractions represent the proenzyme form.



cisely determined. Thus, for example, although smoking seems to be a risk factor for IPF (3), it appears to confer some protection for survival, putatively because it reduces fibroblastic foci (20, 21). Furthermore, heavy smokers may develop first pulmonary emphysema and then pulmonary fibrosis of unknown etiology (14).

In this work, we observed that tobacco smoke exposure increased the number of myofibroblasts in the alveolar septa and exacerbated the lung fibrotic response to bleomycin. However, this effect was more severe in guinea pigs where smoking preceded the exposure to the fibrogenic injuring agent. It is important to emphasize that this experimental group is different from the other that also received tobacco smoke and bleomycin in the fact that the lungs were already injured when they received the bleomycin.

An earlier report by Osanai et al. (32) found that tobacco smoke reduced the fibrotic response to bleomycin. However, this study was performed on hamsters and is difficult to compare directly with ours, which is on guinea pigs. Both our model and the hamster model exhibited statistically significant increases in the neutrophil counts when animals were treated with tobacco smoke and bleomycin. In addition to the species difference, in the hamster model, considerably lower levels of tobacco exposure were used, and animals were studied only 10 days after bleomycin instillation in contrast to the 6 wk used in our study. Perhaps, cigarette smoke in the early phases of bleomycin injury reduces the fibrosis but after prolonged injury leads to increasing damage and increasing fibrosis.

Several mechanisms may account for the smoke-related increase of fibrosis, some occurring by smoking itself whereas others appeared when both aggressions were combined. Regarding the first situation, three events that may enhance a fibrotic response took place when animals were exposed to cigarette smoke alone: 1) a noteworthy increase in neutrophils, 2) an increase in MMP-9 lung activity, and 3) the presence of fibroproliferative factors in BAL.

A higher fibrotic response has been associated with marked accumulation of neutrophils, both in experimental models and human diseases (8, 19), and increased tissue neutrophils loaded with MMP-8 and MMP-9 have been implicated in the fibrotic reaction of patients with chronic hypersensitivity pneumonitis (33).

Upregulation of MMP-9 has been previously documented in human lungs from smokers with COPD as well as in guinea pigs exposed to cigarette smoke (40, 42). There might be a linkage between elevation in MMP-9 activity and increased neutrophils since these inflammatory cells are a major source of MMP-9. Therefore, in pathological processes where neutrophils are abundant, as we found in the BAL of tobacco smoke-exposed guinea pigs, increased MMP-9 is also found. Additionally, MMP-9 is synthesized by a number of different lung cells after injury, including alveolar epithelial cells and macrophages (42, 44). A growing body of evidence strongly suggests that increased MMP-9 activity may contribute to fibrogenesis. MMP-9-deficient mice injured with bleomycin develop considerably fewer lung fibrotic lesions compared with MMP-9<sup>+/+</sup> littermates (4). Likewise, mice deficient in  $\gamma$ -glutamyl transpeptidase, a key enzyme in glutathione and cysteine metabolism, developed a markedly lesser fibrotic response to bleomycin, which was at least partially associated with decreased neutrophils and lower MMP-9 activity in lung tissues (34).

Considering its substrate affinity for type IV collagen, increased MMP-9 activity may lead to the loss of integrity of the basement membranes, which in turn, after a second injury such as bleomycin exposure, could enhance its fibrogenic effect. Another important putative profibrotic effect is related to the ability of cell surface-localized MMP-9 to cleave and activate latent TGF- $\beta$ , a potent profibrotic growth factor (50).

A third possible mechanism that may be involved in the cigarette smoke enhancement of lung fibrosis is the increased fibroblast growth rate activity observed in

the BAL fluid. This was a surprising finding, since, at least in vitro, cigarette smoke extracts reduce viability and inhibit fibroblast proliferation and migration (16, 27, 29).

The characterization of the experimental group with the highest fibrotic response shows that this group displayed an important increase in BAL eosinophils as well as in IL-4 and TIMP-2. IL-4 and TIMP-2 were also found to be increased in the injured lung tissues primarily expressed by interstitial and alveolar macrophages. Both molecules and eosinophils have been documented to play an important role in fibrotic response. IL-4 is a pivotal molecule in the T lymphocyte helper 2 (Th2) response that is able to provoke a profibrotic milieu. IL-4 is a potent activator of the synthesis of a number of extracellular matrix proteins, including collagen and tenascin (13, 23, 35, 45), and also increases fibroblast chemotaxis (36). Furthermore, IL-4 stimulates fibroblast proliferation, and it could have contributed to the further increase of fibroblast proliferation stimulating activity found in the BAL fluid of the TS/B group. Supporting this notion, the use of anti-IL-4 antibody partially decreased the proliferating activity obtained in the BAL fluid of these animals. Therefore, IL-4 could have played a role in the exaggerated lung fibrotic repair caused by smoking and bleomycin. Studies in vivo also support a profibrogenic role for IL-4. Thus the use of neutralizing anti-IL-4 antibodies reduces murine *Schistosoma mansoni*-induced hepatic fibrosis and scleroderma (9, 31). However, a recent report stresses this concept since the severity of bleomycin-induced lung fibrosis was decreased in transgenic mice overexpressing IL-4 compared with knock-out mice lacking IL-4 (17).

On the other hand, increased expression of TIMP-2, an inhibitor of MMP as well as an inductor of cell proliferation, has been found in pulmonary fibrosis (7, 12). Furthermore, TIMP-2 appears to be specifically synthesized by fibroblasts/myofibroblasts in the characteristic fibroblastic foci of IPF lungs (12, 44). Interestingly, an important link between IL-4 and TIMP-2 has been recently reported (15). From a variety of cytokines and growth factors assayed, only IL-4 was demonstrated to induce a dose- and time-dependent induction of TIMP-2 mRNA and protein by dermal fibroblasts.

Another important finding in guinea pigs from the TS/B group is the noteworthy increase in BAL eosinophils, a process that may be at least partially associated with the increase in IL-4 and the Th2-like cytokine network. Eosinophils have been associated with a number of tissue fibrotic conditions (30) and have been shown to act as direct modulatory cells in fibroblast proliferation, collagen synthesis, and lattice contraction, in part, through TGF- $\beta$  (22). Furthermore, TGF- $\beta$ 1-producing eosinophils were predominantly localized within areas of active fibrosis in bleomycin-induced lung injury (52). It has been suggested that fibroblasts and alveolar epithelial cells may modulate eosinophil recruitment into the lung in this experimental model (38). The presence of eosinophils in the lungs of pa-

tients with pulmonary fibrosis has been correlated with poor prognosis or resistance to therapy (5).

In summary, our results demonstrate that exposure to cigarette smoke enhances lung fibrosis induced by bleomycin. This effect seems to be at least partially related with an increase in BAL neutrophils, MMP-9, and fibroproliferative activities. Guinea pigs that were exposed to smoke first and then were injured with bleomycin exhibited the highest fibrotic reaction, which was characterized by a Th2-like milieu.

## DISCLOSURES

This work was supported by Programa de Apoyo a Proyectos de Investigación e Innovación Tecnológica Grant IN-210999.

## REFERENCES

1. Adesina AM, Vallyathan V, McQuillen EN, Weaver SO, and Craighead JE. Bronchiolar inflammation and fibrosis associated with smoking. *Am Rev Respir Dis* 143: 144–149, 1991.
2. Anderson R, Theron AJ, Richards GA, Myer MS, and van Rensburg AJ. Passive smoking by humans sensitizes circulating neutrophils. *Am Rev Respir Dis* 144: 570–574, 1991.
3. Baumgartner KB, Samet JM, Stidley CA, Colby TV, and Waldron JA. Cigarette smoking: a risk factor for idiopathic pulmonary fibrosis. *Am J Respir Crit Care Med* 155: 242–248, 1997.
4. Betsuyaku T, Fukuda Y, Parks WC, Shipley JM, and Senior RM. Gelatinase B is required for alveolar bronchiolization after intratracheal bleomycin. *Am J Pathol* 157: 525–535, 2000.
5. Boomars KA, Wagenaar SS, Mulder PGH, Velzen-Blad H, and van den Bosch JMM. Relationship between cells obtained by bronchoalveolar lavage and survival in idiopathic pulmonary fibrosis. *Thorax* 50: 1087–1092, 1995.
6. Braun KM, Cornish T, Valm A, Cundiff J, Pauly JL, and Fan S. Immunotoxicology of cigarette smoke condensates: suppression of macrophage responsiveness to interferon gamma. *Toxicol Appl Pharmacol* 149: 136–143, 1998.
7. Brew K, Dinakarandian D, and Nagase H. Tissue inhibitors of metalloproteinases: evolution, structure and function. *Biochim Biophys Acta* 1477: 267–283, 2000.
8. Cailles JB, O'Connor C, Pantelidis P, Southcott AM, Fitzgerald MX, Black CM, and du Bois RM. Neutrophil activation in fibrosing alveolitis: a comparison of lone cryptogenic fibrosing alveolitis and systemic sclerosis. *Eur Respir J* 9: 992–999, 1996.
9. Cheever AW, Williams ME, Wynn TA, Finkelman FD, Seder RA, Cox TM, Hieny S, Caspar P, and Sher A. Anti-IL-4 treatment of *Schistosoma mansoni*-infected mice inhibits development of T cells and non-B, non-T cells expressing Th2 cytokines while decreasing egg-induced hepatic fibrosis. *J Immunol* 153: 753–759, 1994.
10. Depierre A, Dalphin JC, Pernet D, Dubiez A, Faucompre C, and Breton JL. Epidemiological study of farmer's lung in five districts of the French Doubs province. *Thorax* 43:429–435, 1988.
11. Douglas JG, Middleton WG, Gaddie J, Petrie GR, Choo-Kang YF, Prescott RJ, and Crompton GK. Sarcoidosis: a disorder commoner in non-smokers? *Thorax* 41: 787–791, 1986.
12. Fukuda Y, Ishizaki M, Kudoh S, Kitaichi M, and Yamanaka N. Localization of matrix metalloproteinases-1, -2, and -9 and tissue inhibitor of metalloproteinase-2 in interstitial lung diseases. *Lab Invest* 78: 687–698, 1998.
13. Gillery P, Fertin C, Nicolas JF, Chastang F, Kalis B, Banchereau J, and Maquart FX. Interleukin-4 stimulates collagen gene expression in human fibroblast monolayer cultures. Potential role in fibrosis. *FEBS Lett* 302: 231–234, 1992.
14. Hiwatari N, Shimura S, and Takishima T. Pulmonary emphysema followed by pulmonary fibrosis of undetermined cause. *Respiration* 60: 354–358, 1993.
15. Ihn H, Yamane K, Asano Y, Kubo M, and Tamaki K. IL-4 up-regulates the expression of tissue inhibitor of metalloprotein-



- ase-2 in dermal fibroblasts via the p38 mitogen-activated protein kinase-dependent pathway. *J Immunol* 168: 1895–1902, 2002.
16. **Ishii T, Matsuse T, Igarashi H, Masuda M, Teramoto S, and Ouchi Y.** Tobacco smoke reduces viability in human lung fibroblasts: protective effect of glutathione *S*-transferase P1. *Am J Physiol Lung Cell Mol Physiol* 280: L1189–L1195, 2001.
  17. **Izbicki G, Or R, Christensen TG, Segel MJ, Fine A, Goldstein RH, and Breuer R.** Bleomycin-induced lung fibrosis in IL-4-overexpressing and knockout mice. *Am J Physiol Lung Cell Mol Physiol* 283: L1110–L1116, 2002.
  18. **Johansson S, Bjermer L, Franzen L, and Henriksson R.** Effects of ongoing smoking on the development of radiation-induced pneumonitis in breast cancer and oesophagus cancer patients. *Radiother Oncol* 49: 41–47, 1998.
  19. **Jones HA, Schofield JB, Krausz T, Boobis AR, and Haslett C.** Pulmonary fibrosis correlates with the duration of tissue neutrophil activation. *Am J Respir Crit Care Med* 158: 620–628, 1998.
  20. **King TE Jr, Schwarz MI, Brown K, Tooze JA, Colby TV, Waldron JA Jr, Flint A, Thurlbeck W, and Cherniack RM.** Idiopathic pulmonary fibrosis: relationship between histopathologic features and mortality. *Am J Respir Crit Care Med* 164: 1025–1032, 2001.
  21. **King TE Jr, Tooze JA, Schwarz MI, Brown KR, and Cherniack RM.** Predicting survival in idiopathic pulmonary fibrosis: scoring system and survival model. *Am J Respir Crit Care Med* 164: 1171–1181, 2001.
  22. **Levi-Schaffer F, Garbuzenko E, Rubin A, Reich R, Pickholz D, Gillery P, Emonard H, Nagler A, and Maquart FA.** Human eosinophils regulate human lung- and skin-derived fibroblast properties in vitro: a role for transforming growth factor beta (TGF-beta). *Proc Natl Acad Sci USA* 96: 9660–9665, 1999.
  23. **Makhluf HA, Stepniakowska J, Hoffman S, Smith E, LeRoy EC, and Trojanowska M.** IL-4 upregulates tenascin synthesis in scleroderma and healthy skin fibroblasts. *J Invest Dermatol* 107: 856–859, 1996.
  24. **McCawley LJ and Matrisian LM.** Matrix metalloproteinases: they're not just for matrix anymore. *Curr Opin Cell Biol* 13: 534–540, 2001.
  25. **Murin S, Smith Bilello K, and Matthey R.** Other smoking-affected pulmonary diseases. *Clin Chest Med* 21: 121–137, 2000.
  26. **Myers JL, Veal CF Jr, Shin MS, and Katzenstein ALA.** Respiratory bronchiolitis causing interstitial lung disease. A clinicopathologic study of six cases. *Am Rev Respir Dis* 135: 880–884, 1987.
  27. **Nakamura Y, Romberger DJ, Tate L, Ertl RF, Kawamoto M, Adachi Y, Mio T, Sisson JH, Spurzem JR, and Rennard SI.** Cigarette smoke inhibits lung fibroblast proliferation and chemotaxis. *Am J Respir Crit Care Med* 151: 1497–1503, 1995.
  28. **Nilsson K, Henriksson R, Cai YQ, Hellstrom S, Hornqvist Bylunds S, and Bjermer L.** Effects of tobacco-smoke on radiation-induced pneumonitis in rats. *Int J Radiat Biol* 62: 719–727, 1992.
  29. **Nobukuni S, Watanabe K, Inoue J, Wen FQ, Tamaru N, and Yoshida M.** Cigarette smoke inhibits the growth of lung fibroblasts from patients with pulmonary emphysema. *Respirology* 7: 217–223, 2002.
  30. **Noguchi H, Kephart GM, Colby TV, and Gleich GJ.** Tissue eosinophilia and eosinophil degranulation in syndromes associated with fibrosis. *Am J Pathol* 140: 521–528, 1992.
  31. **Ong F, Wong C, Roberts CR, Teh HS, and Jirik FR.** Anti-IL-4 treatment prevents dermal collagen deposition in the tight-skin mouse model of scleroderma. *Eur J Immunol* 28: 2619–2629, 1998.
  32. **Osanai K, Takahashi K, Suwabe A, Takada K, Ikeda H, Sato S, and Yasui S.** The effect of cigarette smoke on bleomycin-induced pulmonary fibrosis in hamsters. *Am Rev Respir Dis* 138: 1276–1281, 1988.
  33. **Pardo A, Barrios R, Gaxiola M, Segura-Valdez L, Carrillo G, Estrada A, Mejía M, and Selman M.** Increase of lung neutrophils and upregulation of neutrophil gelatinase B and collagenase in hypersensitivity pneumonitis. *Am J Respir Crit Care Med* 161: 1698–1704, 2000.
  34. **Pardo A, Ruiz V, Arreola JL, Ramírez R, Cisneros-Lira J, Gaxiola M, Barrios R, Kala SV, Lieberman MW, and Selman M.** Bleomycin-induced pulmonary fibrosis is attenuated in  $\gamma$ -glutamyl transpeptidase-deficient mice. *Am J Respir Crit Care Med* 167: 925–932, 2003.
  35. **Postlethwaite AE, Holness MA, Katai H, and Raghov R.** Human fibroblasts synthesize elevated levels of extracellular matrix protein in response to interleukin 4. *J Clin Invest* 90: 1479–1485, 1992.
  36. **Postlethwaite AE and Seyer JM.** Fibroblast chemotaxis induction by human recombinant interleukin-4: identification by synthetic peptide analysis of two chemotactic domains residing in amino acid sequences 70–88 and 89–122. *J Clin Invest* 87: 2147–2152, 1991.
  37. **Ramos C, Montaña M, García-Alvarez J, Ruiz V, Uhal BD, Selman M, and Pardo A.** Fibroblasts from idiopathic pulmonary fibrosis and normal lungs differ in growth rate, apoptosis, and TIMP's expression. *Am J Respir Cell Mol Biol* 24: 591–598, 2001.
  38. **Sato E, Koyama S, and Robbins RA.** Bleomycin stimulates lung fibroblast and epithelial cell lines to release eosinophil chemotactic activity. *Eur Respir J* 16: 951–958, 2000.
  39. **Schwarz MI.** Approach to the understanding, diagnosis, and management of interstitial lung disease. In: *Interstitial Lung Disease*, edited by Schwarz MI and King TE. Hamilton, Ontario, Canada: Decker, 1998, p. 3–30.
  40. **Segura L, Pardo A, Gaxiola M, Uhal BD, Becerril C, and Selman M.** Upregulation of gelatinases A and B, collagenases 1 and 2, and increased parenchymal cell death in COPD. *Chest* 117: 684–694, 2000.
  41. **Selman M.** Hypersensitivity pneumonitis. In: *Interstitial Lung Disease*, edited by Schwarz MI and King TE. Hamilton, Ontario, Canada: Decker, 1998, p. 393–422.
  42. **Selman M, Cisneros-Lira J, Gaxiola M, Ramírez R, Kudlacz EM, Mitchell PG, and Pardo A.** Matrix metalloproteinases inhibition abrogates tobacco smoke-induced emphysema in guinea pigs. *Chest* 123: 1633–1641, 2003.
  43. **Selman M, Montaña M, Ramos C, Vanda B, Becerril C, Delgado J, Sansores R, Barrios R, and Pardo A.** Tobacco smoke-induced lung emphysema in guinea pigs is associated with increased interstitial collagenase. *Am J Physiol Lung Cell Mol Physiol* 271: L734–L743, 1996.
  44. **Selman M, Ruiz V, Cabrera S, Segura L, Ramírez R, Barrios B, and Pardo A.** TIMP-1, -2, -3, and -4 in idiopathic pulmonary fibrosis. A prevailing nondegradative lung microenvironment? *Am J Physiol Lung Cell Mol Physiol* 279: L562–L574, 2000.
  45. **Sempowski GD, Beckmann MP, Derdak S, and Phipps RP.** Murine lung fibroblasts express membrane-bound and soluble IL-4 receptors. Role of IL-4 in enhancing fibroblast proliferation and collagen synthesis. *J Immunol* 152: 3606–3614, 1994.
  46. **Takizawa H, Tanaka M, Takami K, Ohtoshi T, Ito K, Satoh M, Okada Y, Yamasawa F, Nakahara K, and Umeda A.** Increased expression of transforming growth factor-beta1 in small airway epithelium from tobacco smokers and patients with chronic obstructive pulmonary disease (COPD). *Am J Respir Crit Care Med* 163: 1476–1483, 2001.
  47. **Travis WD, Borok Z, Roum JH, Zhang J, Feuerstein I, Ferrans VJ, and Crystal RG.** Pulmonary Langerhans cell granulomatosis (histiocytosis X): a clinicopathologic study of 48 cases. *Am J Surg Pathol* 17: 971–986, 1993.
  48. **Woessner JF.** The determination of hydroxyproline in tissue and protein samples containing small proportions of this imino acid. *Arch Biochem Biophys* 93: 440–447, 1961.
  49. **Yousem SA, Colby TV, and Gaensler EA.** Respiratory bronchiolitis-associated interstitial lung disease and its relationship to desquamative interstitial pneumonia. *Mayo Clin Proc* 64: 1373–1380, 1989.
  50. **Yu Q and Stamenkovic I.** Cell surface-localized matrix metalloproteinase-9 proteolytically activates TGF-beta and promotes tumor invasion and angiogenesis. *Genes Dev* 14: 163–176, 2000.
  51. **Yu W and Woessner F Jr.** Heparin-enhanced zymographic detection of matrilysin and collagenases. *Anal Biochem* 293: 38–42, 2001.
  52. **Zhang K, Flanders KC, and Phan SH.** Cellular localization of transforming growth factor-beta expression in bleomycin-induced pulmonary fibrosis. *Am J Pathol* 147: 352–361, 1995.